

Surgical Techniques

Lung Transplant and Lung Volume Reduction

Carlos Henrique R. Boasquevisque¹, Erkan Yildirim¹, Thomas K. Waddel¹, and Shaf Keshavjee¹

¹Lung Transplant Program, Department of Surgery, Toronto General Hospital, University of Toronto, Toronto, Ontario, Canada

Patients with end-stage emphysema can be offered lung volume

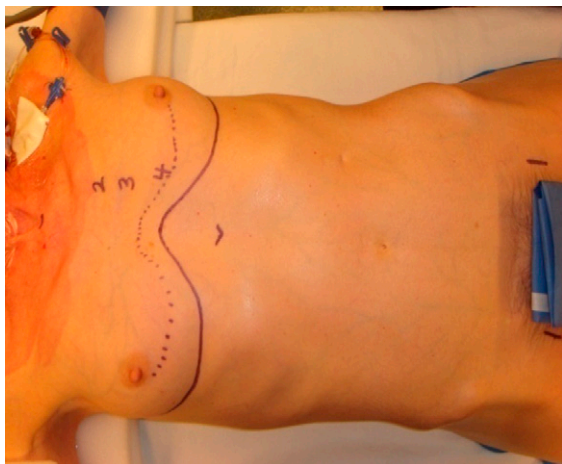


Figure 1. Patient positioned for bilateral lung transplant, through a clamshell incision with the arms abducted. The skin incision is depicted in the mammary fold heading laterally toward the mid-axillary line. The dotted line shows the level of the 4th intercostal space. The position of the femoral artery, on both sides, is also marked. The groin is prepped and draped, since during the transplant procedure, an arterial femoral line may become necessary for monitoring or even for cannulation for cardiopulmonary bypass.

and bronchiectasis, we first use a single lumen tube and bronchoscopy is performed for airway toilette and bronchial washing for microbiological cultures. A left-sided double lumen tube is then inserted to allow one-lung ventilation.

For induction, propofol, penthotal, midazolam, and ketamine have been used at TGH in combination with narcotic analgesics such as fentanyl (10 to 15 µg/kg) or sufentanyl. Pancuronium is the most frequently used relaxant. Nitrous oxide is never used because it increases pulmonary vascular resistance (PVR) and expands intravascular gas emboli, which may be entrapped in the graft. Isoflurane or sevoflurane are used initially for maintenance of anesthesia, but the patient may not tolerate well once he or she becomes hemodynamically unstable due to mediastinal manipulation or vasodilatory hypotension. Propofol infusion at a rate of 50 mg/kg/min ensures amnesia. Supplemental doses of fentanyl are administered every 2 to 3 hours (5 µg/kg) (4).

After the anesthesia is induced, a Swan-Ganz catheter is inserted through the right jugular vein and a central venous catheter is inserted into the jugular or subclavian vein.

A nasopharyngeal temperature probe and Foley catheter are also inserted. A warming blanket is used to cover the upper thorax and the legs (4).

Transesophageal echocardiogram is used to monitor the right ventricular function and biventricular filling. It may also be used to evaluate the venous pulmonary blood flow at the end of the transplant procedure (4).

In severe pulmonary hypertension, one-lung ventilation is not attempted. Increased expiratory time is necessary in patients with severe obstructive airway disease to avoid gas trapping and auto-PEEP (4).

Permissive hypercarbia is usually required, and pH is a better determinant of the inability to ventilate than is PaCO₂ (4).

In the following sections we present the technique for bilateral lung transplantation, step by step.

Step 1: Patient Position

For bilateral lung transplant, the recipient is positioned supine with the arms abducted (Figure 1). In patients with emphysema, who have a bigger anterior-posterior diameter, the arms can be positioned alongside.

For unilateral lung transplant, the recipient can be positioned in full lateral decubitus or supine. When positioned supine for a single lung transplant, the incision can be an anterolateral thoracotomy and the sternum can be cut to improve exposure or if cardiopulmonary bypass becomes necessary.

It is important to watch the position of the arms so they are not overstretched during the whole procedure, avoiding brachial plexus injury. Proper padding of the arms and legs is also important. Thrombo-embolic deterrent (TED) stockings and compressive device are used for prophylaxis of deep venous thrombosis.

Step 2: Clamshell Incision

Our incision of choice is the clamshell incision, with sternal transection. Others have performed bilateral lung transplantation through median sternotomy or anterolateral thoracotomies with sternal sparing (5). Two separate posterolateral incisions have also been used.

After prepping and draping, the skin incision is performed in the mammary fold. A short skin flap is raised with cautery to the level of the fourth intercostal space, and the pectoralis muscle is cut at this level.

The fourth intercostal space is entered laterally, and a rib spreader can be placed to aid in the dissection of the mammary vessels, close to the sternum (Figure 2).

After the mammary vessels have been transected, the mediastinal tissue underneath the sternum is dissected and the sternum is cut with a sternal saw. The sternal saw is positioned in such a way as to cut the sternum obliquely (Figure 3). This is to improve stability and decrease the chance of sternal overriding after closure of the clamshell incision.

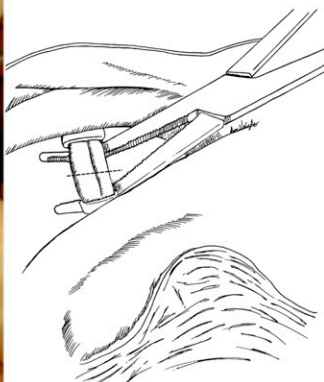
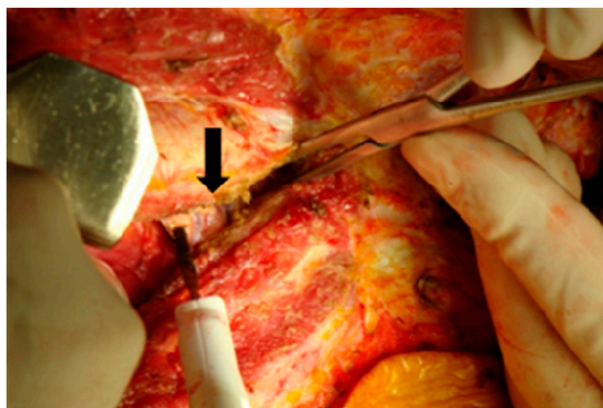


Figure 2. The head is to the top and feet to the bottom. The pleural cavity is entered laterally in the 4th intercostal space, and a rib spreader is placed to improve the exposure of the mammary vessels (black arrow). The mammary vessels can be secured with large clips or applying clamps and tying with 2-0-silk ties.

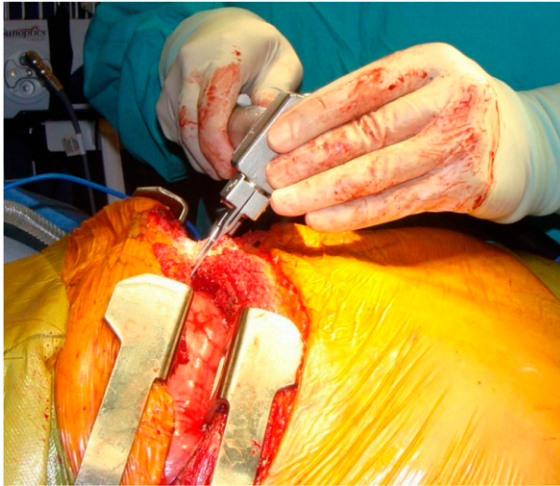


Figure 3. We prefer to transect the sternum as depicted in the drawing. The head is to the left and the feet to the right. The sternum is cut in an oblique fashion to avoid sternal overriding postoperatively.

After hemostasis, sternal retractors are placed bilaterally and are opened gradually as the retrosternal mediastinal tissue is cut, to obtain good exposure of aorta and the right atrium if cardiopulmonary bypass is required at any point of the transplant procedure (Figure 4).

Step 3: Pneumonectomy

As a general rule, in bilateral sequential lung transplantation, the first lung to be transplanted is the one with least perfusion demonstrated on the V/Q scan.

For the purpose of illustration, in the next steps we will show the transplant procedure done on the right side.

The lung is collapsed and the pleura over the pulmonary hilum and the inferior pulmonary ligament are incised. Hypoxia is common during one-lung ventilation due to intrapulmonary shunt in the nonventilated lung and improves considerably when the pulmonary blood flow to the nonventilated lung is stopped by occluding the pulmonary artery (PA) (4). The superior pulmonary vein, pulmonary artery, and inferior pulmonary vein are dissected and divided (Figures 5 and 6).

Hypoxia, progressive hypercarbia, and persistent low pH (< 7.2) with hemodynamic instability may require cardiopul-

monary bypass (CPB). Cardiopulmonary bypass is used at TGH in approximately 35% of cases (4). Cardiopulmonary bypass may be initiated:

1. Electively in patients with reduced pulmonary vascular bed, pulmonary arterial hypertension, in those undergoing lobar transplantation, and when coronary artery bypass graft or cardiac repair such as atrial septal defect or ventricular septal defect are anticipated (4).
2. During the implantation of the first allograft, when the diseased native lung is not able to maintain adequate gas exchange or if hemodynamic instability not controlled by vasoactive agents ensues.

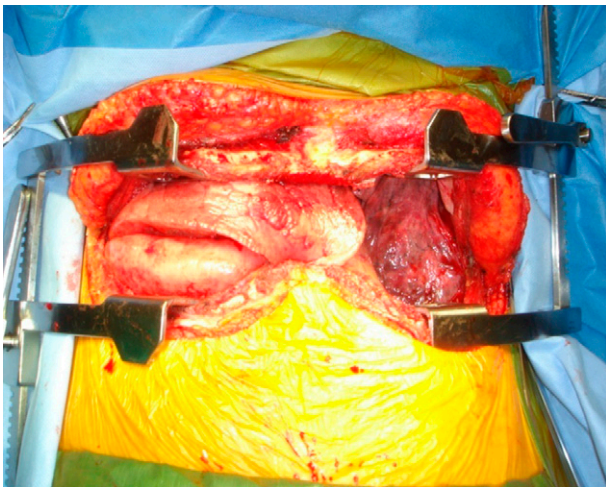


Figure 4. The head is to the top and feet to the bottom. This incision provides excellent exposure of the mediastinum and both pleural spaces. The left lung has been collapsed for hilar dissection.

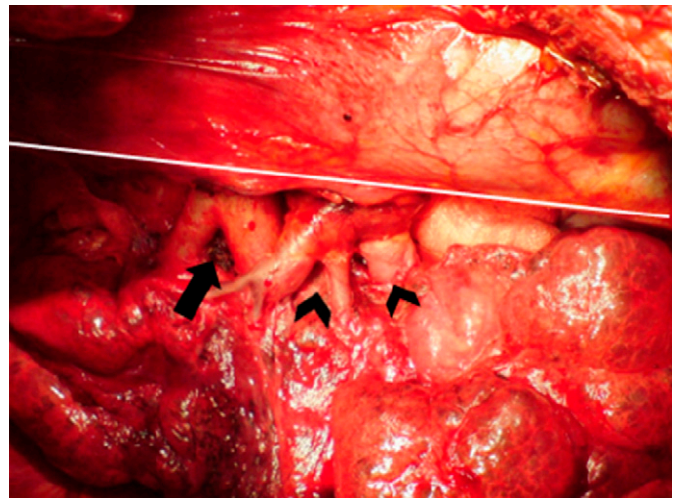
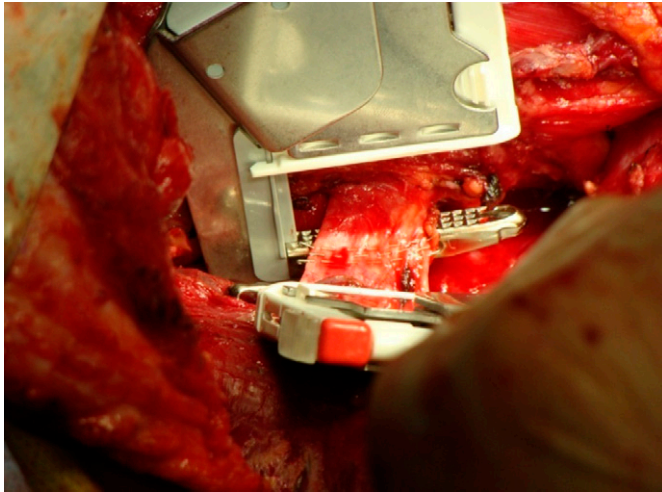


Figure 5. Anterior view of the dissected right pulmonary hilum. The mediastinum is to the top and the native lung to the bottom. From left to right: pulmonary artery (black arrow), superior pulmonary vein, and inferior pulmonary vein, respectively (black arrowheads). The bronchus is posterior. Injury to the phrenic nerve (white line) is avoided during the hilar dissection or during mediastinum retraction for hilar exposure. We prefer to expose the mediastinum by retracting the structures with the assistant's hand over a folded sponge. Hypotension can occur during this maneuver, and one should watch for this. The left hilum exposure may be more difficult because of the heart, requiring more retraction and causing hypotension more frequently.



←
Figure 6. The mediastinum is at the *top* and the lung at the *bottom*. The head is to the *left* and the feet are to the *right*. After tying the superior division of the right pulmonary artery, two vascular staplers are applied to the superior pulmonary vein, very close to the native lung, to have a good length of pulmonary vein for the venous anastomosis. When the superior pulmonary vein is stapled and divided, the inferior division of the right pulmonary artery can be well visualized, and two staplers are applied close to the lung. The same maneuver is applied to the inferior pulmonary vein.

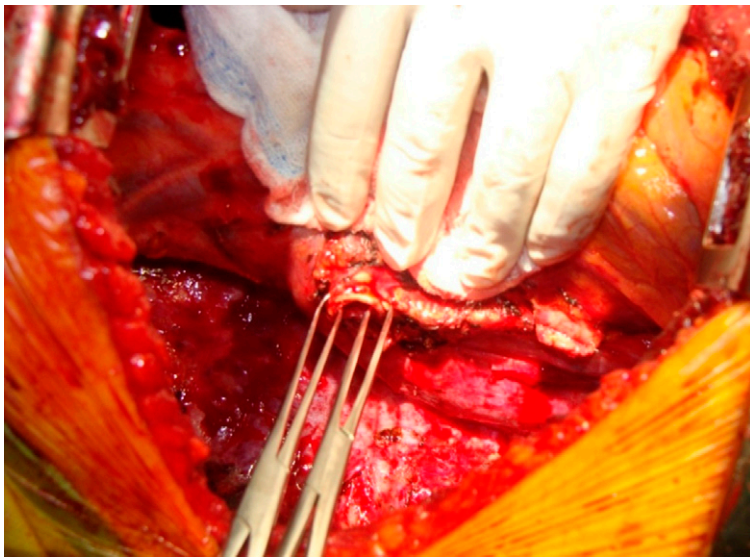


Figure 7. The right bronchus is trimmed back toward the mediastinum. Allis clamps are applied at both corners of the bronchus. The surgeon or the first assistant holds the clamps, and the surgeon dissects the peribronchial tissue toward the mediastinum to the level of bronchial amputation. Care is taken not to excessively strip the peribronchial tissue away from the wall of the bronchus.

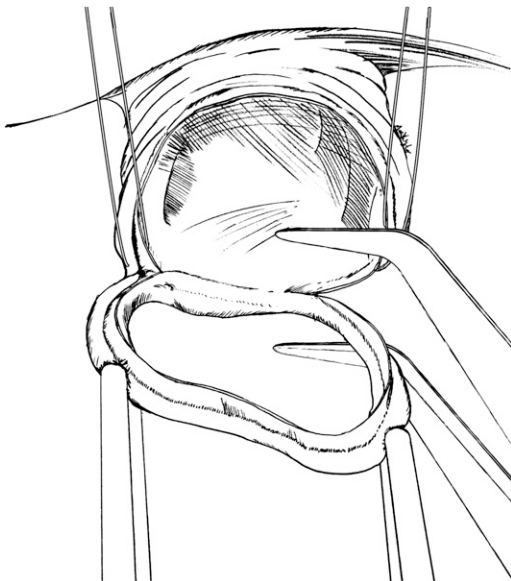


Figure 8. The cartilaginous wall, but not the membranous wall, is cut with a # 15 blade scalpel. 3-0 Vicryl or 3-0 PDS holding sutures are placed at the cartilaginous corners. The needles are not cut. Then, the membranous portion is cut with valve scissors.

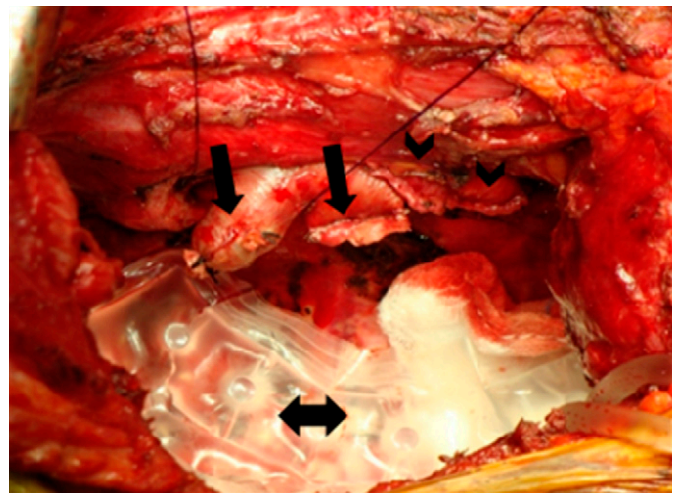


Figure 9. The mediastinum is to the *top*. The superior and inferior division of the pulmonary artery (*black arrows*) and the superior and inferior pulmonary vein stumps (*black arrowheads*) are shown. Once all hilar structures are dissected and hemostasis is confirmed, particularly in the posterior mediastinum, a sponge at first and then a cooling jacket (*double arrow*) are placed in the pleural cavity. The allograft will lie on the cooling jacket during the implantation.

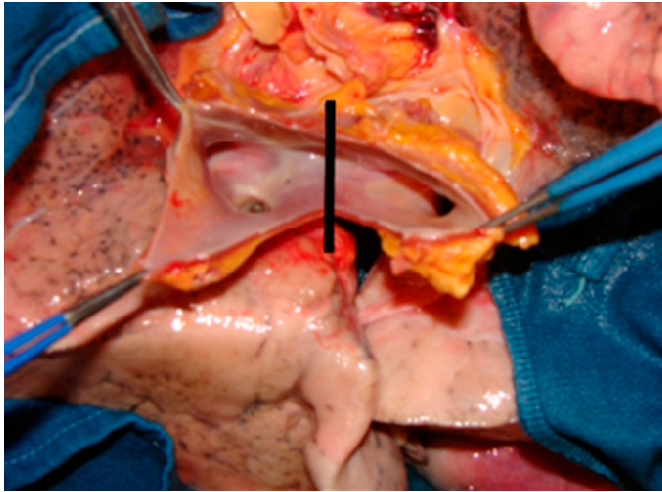


Figure 10. To separate the lungs, the atrial cuff is transected in the midline (*black line*).

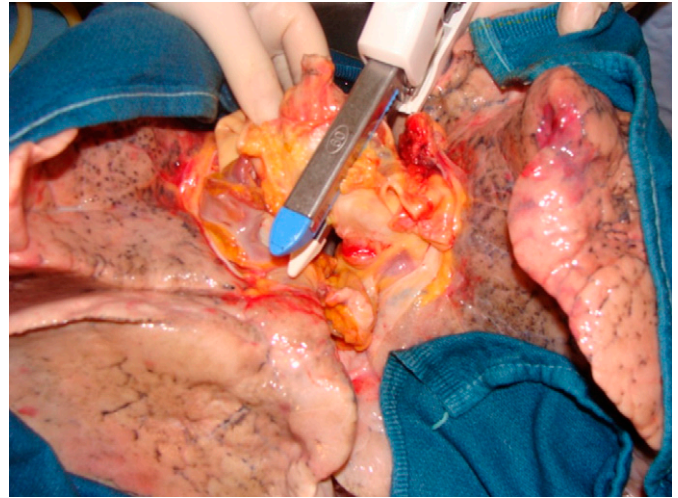


Figure 12. The left main bronchus is divided with a GIA linear stapler, so the lungs remain inflated until implantation.

3. During the implantation of the second allograft, since the first implanted lung receives the entire cardiac output and worsening of pulmonary edema may occur with poor oxygenation, hypercarbia, and hemodynamic instability (4).

Patients with idiopathic pulmonary fibrosis also have an increased need for cardiopulmonary bypass support (4).

If CPB is required for hemodynamic or ventilatory support, the heart remains warm and beating. If cardiac repair is necessary, such as for atrial septal defect or ventricular septal defect, the heart is arrested and moderately cooled (4).

Cardiopulmonary bypass unloads the right side of the heart and improves hemodynamic stability. On the other hand, CPB may cause (1) coagulopathy due to hemodilution, heparinization, and platelet dysfunction; (2) hemolysis due to red blood cell trauma; or (3) activation of complement, neutrophils, and systemic inflammatory response, which may contribute to allograft injury at reperfusion (4).

When lung transplant is performed through the clamshell incision or through a right thoracotomy, the right atrium and the ascending aorta are cannulated for CPB.

When left single lung transplant is performed through a left thoracotomy, the main pulmonary artery and the descending aorta are cannulated. Others prefer to perform a left single lung transplant by means of a left anterolateral thoracotomy with sternal division and to cannulate the ascending aorta and atrium, if CPB is necessary.

At TGH, we have also used bicaval cannulation instead of a double-stage cannula inserted through the right atrium. We have noticed less systemic hypotension during mediastinal manipulation when we use the bicaval cannulation.

The last structure to be divided is the bronchus. Hemostasis is carefully obtained, chiefly in patients with cystic fibrosis and bronchiectasis who may have enlarged bronchial arteries and enlarged lymph nodes as well. The bronchus is divided immediately proximal to the upper lobe bronchus takeoff.

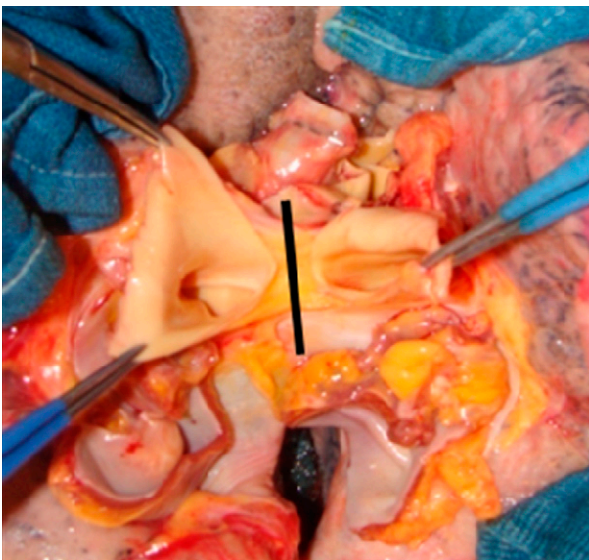


Figure 11. Then, the right and left pulmonary arteries are divided at the main pulmonary artery bifurcation (*black line*).

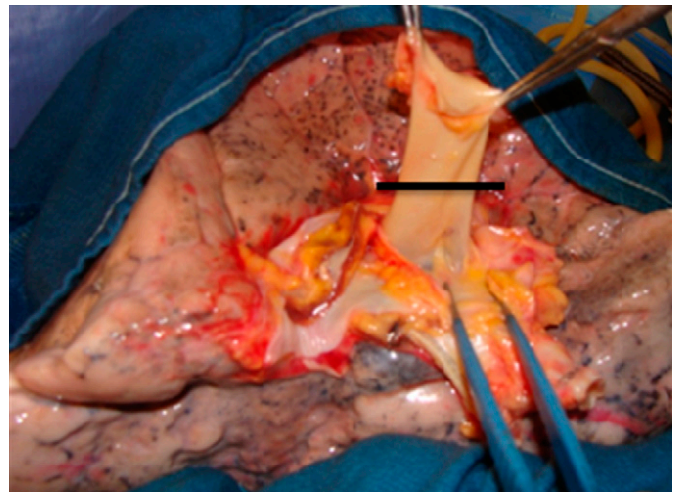


Figure 13. The right pulmonary artery has been dissected under the adventitial plane. The first branch of PA is identified and it serves as a landmark to avoid twisting of the anastomosis. The donor PA is cut appropriately short (*black line*), so there will be no kinking at the anastomotic site.

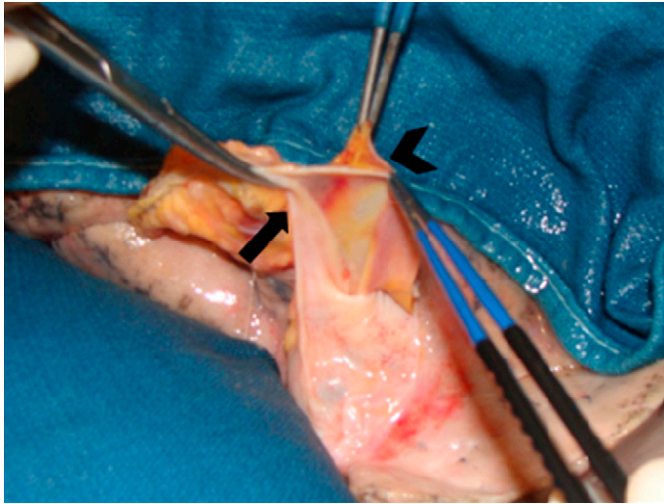


Figure 14. The left atrium (*black arrowhead*) is freed from the pericardial attachments (*black arrow*). The left atrium is dissected very close to its wall on the anterior aspect of the hilum so the pericardium (*black arrow*) over the bronchus is not dissected, preserving its vascularization. This is an important step to avoid ischemic bronchial complications. In the picture, the *blue forceps* are holding the atrial cuff, and the *Kelly clamp* is holding the pericardium/peribronchial tissue flap, which is preserved to cover the bronchial anastomosis.

Step 4: Hilar Dissection for Allograft Implantation

Before implanting the allograft, the pulmonary hilum has to be prepared for the anastomoses. The pulmonary hilum is prepared in the following sequence: bronchus → pulmonary veins → pulmonary artery, as depicted in the Figures 7, 8, and 9. It is extremely important not to devascularize the recipient bronchial stump during dissection to avoid ischemic complications.

Next, Judd-Allis clamps are applied to the venous stumps. The pericardium is opened around the pulmonary veins, so that a good length of left atrium is obtained to apply the atrial clamp at the time of atrial anastomosis.

Then, two Judd-Allis clamps are applied to the pulmonary artery, and the adventitial tissue around PA is carefully dissected. The mediastinal tissue posterior to PA will be used to cover the bronchus together with the donor peribronchial tissue, after the bronchial anastomosis is completed.

Step 5: Allograft Separation and Dissection (Back Table)

The lungs to be implanted are separated and dissected on a back table, at the recipient hospital (Figures 10, 11, and 12). If two single lung transplants are to be done for two recipients, the separation can be done at the donor hospital and the allografts can then be transported separately to the recipient hospital(s).

Next, we dissect the hilum of each allograft, so that the bronchus, pulmonary artery, and the atrial cuff are well individualized for the anastomoses. Once again, it is important to be careful not to excessively strip the donor bronchus of its peribronchial connective tissue that carries important peribronchial blood vessel collaterals.

The donor PA is cut appropriately short, so there will be no kinking at the anastomotic site (Figure 13). At least 5 mm of atrium is left around the pulmonary veins. The left atrium is dissected very close to its wall on the anterior aspect of the hilum so that the pericardium over the bronchus is not dissected, preserving its vascularization (Figure 14). This is an important step to avoid ischemic bronchial complications.

The bronchus is left closed until the implantation is started, at which point it is cut 2 mm proximal to the upper lobe takeoff.

Step 6: Implantation

Once the allograft is dissected and ready to be implanted, the bronchus is opened with a # 15 blade scalpel. The

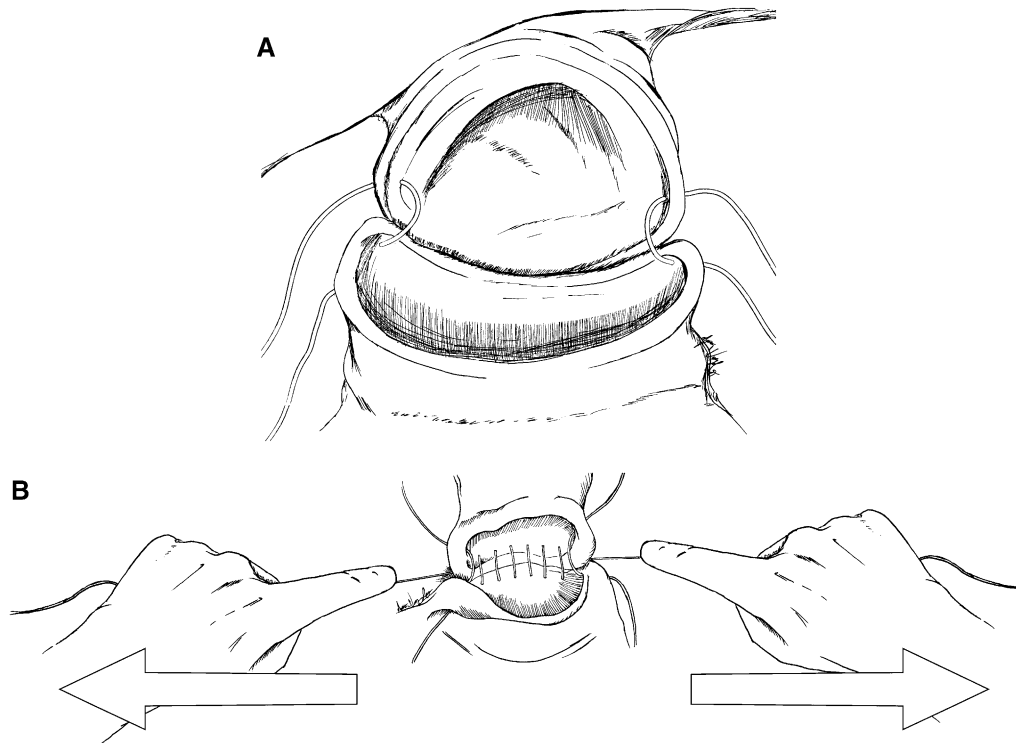


Figure 15. (A) The recipient bronchus is to the *top* and the donor bronchus is to the *bottom*. The previously placed corner sutures (3-0 Vicryl), are now placed at the corner of the donor bronchus. They are not tied. These corner sutures are placed under traction to facilitate exposure. Direct handling of the bronchus with tissue forceps is minimized to avoid tissue trauma. The membranous portion of the anastomosis is performed first, with a running 4-0 PDS or 4-0 Maxon. On the right side, we start at the bottom corner of the recipient bronchus (out-in) and then at the bottom corner of the donor bronchus (in-out), and so on. The membranous portion is sutured from the bottom corner to the top corner. The sutures are left loose at this point, so there is more room to handle the needle as the suture is being performed. (B) The recipient bronchus is to the *top* and the donor bronchus is to the *bottom*. When the membranous portion is completed, the surgeon carefully pulls the PDS corner sutures to tighten the membranous wall suture as depicted.

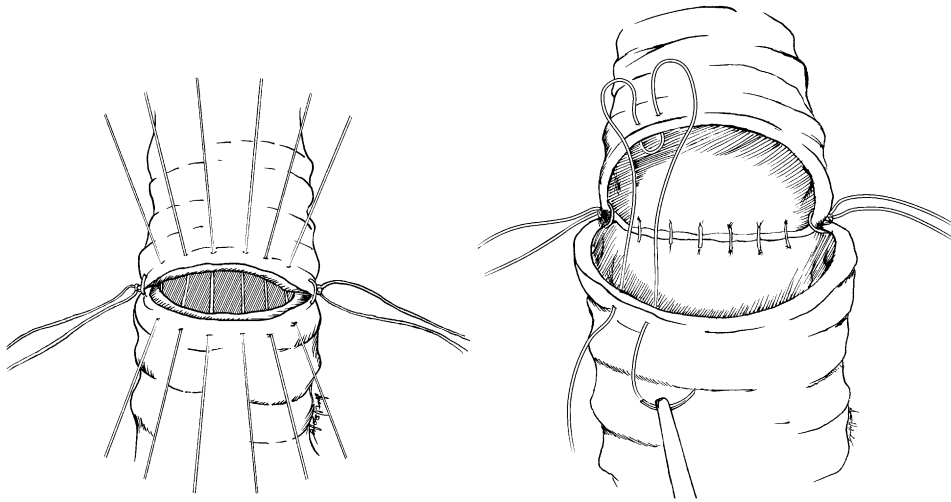


Figure 16. The mediastinum is to the *top* and the donor lung is to the *bottom*. Next, the cartilaginous wall is sutured with 4-0 (or 3-0) Prolene. When there is a good size match between donor and recipient bronchi, we perform an end-to-end anastomosis with simple sutures (~6-7 sutures), as shown on the *left*. When there is a size mismatch we perform a telescoping anastomosis (~5 sutures), as shown on the *right*. When feasible, we prefer to telescope the donor bronchus outside, as depicted in the figure, so that the well-vascularized recipient bronchus can serve as a “stent” to the relatively more ischemic donor bronchus.

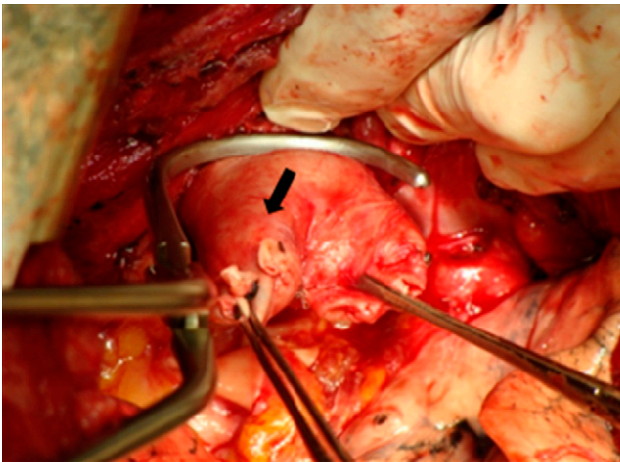


Figure 17. The mediastinum is to the *top* and the donor lung is to the *bottom*. The assistant is pulling on the mediastinum to expose the PA. This maneuver can cause hypotension. One or two Judd-Allis clamps are applied to the pulmonary artery stump. A PA clamp is applied in such a way as to provide a good length of pulmonary artery for the anastomosis. The first branch of the pulmonary artery (*black arrow*) is used as a landmark to place the corner sutures and to avoid twisting the anastomosis.

allograft is then placed on the cooling jacket in the pleural cavity.

The anastomoses start from the most posterior to the most anterior hilar structure (bronchus → pulmonary artery → atrial cuff).

At the end, the bronchial anastomosis is covered. The peribronchial tissue is sutured to the mediastinal tissue behind the pulmonary artery (Figures 15 and 16).

The second anastomosis to be performed is the pulmonary artery anastomosis (Figures 17, 18, and 19).

The last anastomosis to be performed is the atrial anastomosis (Figure 20).

Next, both pulmonary veins are opened, cutting just below the staple lines, to maximize the length of the atrial cuff. The bridge of atrial tissue between both pulmonary veins is cut to create a single recipient atrial cuff.

In the next figures, we show step by step how to perform a running everting mattress suture for the atrial anastomosis (Figures 21, 22, and 23).

After reperfusion of the first implanted allograft, ventilation/perfusion mismatch may occur. Ventilation may go preferentially to the compliant allograft and perfusion to the diseased native lung because the vasculature of the allograft is initially vaso-

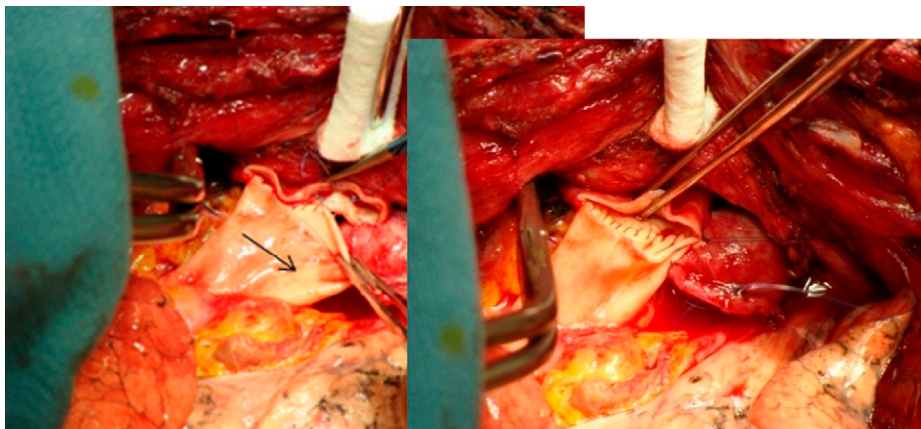


Figure 18. The 5-0 Prolene bottom corner suture is placed first and not tied. Then the top corner suture is placed and tied. The back wall of the PA anastomosis is performed using a running the suture from the top to the bottom corner, as indicated by the *black arrow*.

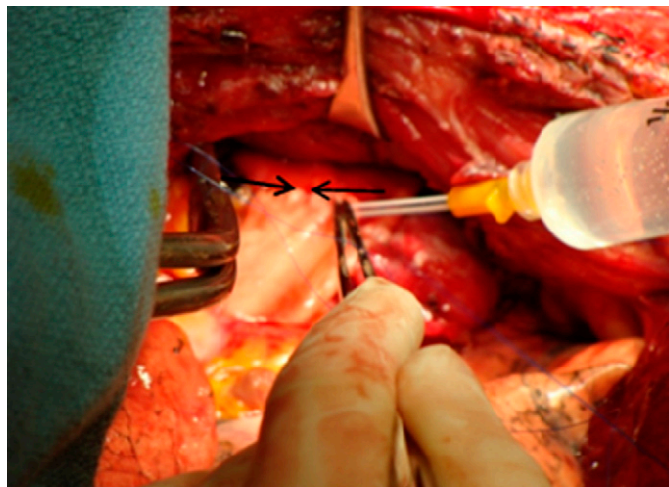


Figure 19. The front wall is started from the bottom corner to the middle and then from the top corner to the middle of the front wall, as indicated by the *black arrows*. Before tying the two sutures in the middle of the front wall, we fill the pulmonary artery with normal saline for de-airing with the aid of a 14-G angiocatheter on a 20-cc syringe, as shown in the figure.

constricted. Cardiopulmonary bypass may be necessary at this point due to hypoxia, hypercarbia, or hemodynamic instability. Clamping the native lung PA may avoid CPB at this point, but on the other hand, as it forces the cardiac output through the newly implanted lung, it may worsen primary graft dysfunction, leading to high PA pressures and right ventricle dysfunction. Inhaled nitric oxide (5–40 ppm) and PGE1 infusion (0.01–0.1 mg/kg/min) may improve the reperfusion injury syndrome. Right ventricle dysfunction is treated with milrinone using a loading dose of 50 mg/kg followed by 0.5 mg/kg/minute (4).

If hypoxia occurs in the presence of systemic hypotension, improving hemodynamics may improve the gas exchange. Systemic hypotension due to mediastinal manipulation and vasodilation are common in lung transplantation. Norepinephrine infusion at a rate of 0.05 mg/kg/minute and titrated to effect is used to treat

systemic hypotension due to low systemic vascular resistance (SVR). Vasopressin 1 to 4 units/hour may be added if not responsive to escalating doses of norepinephrine. Phenylephrine may also be used (100–200 µg bolus) (4).

Arrhythmias are common during mediastinal manipulation, allograft implantation, or after allograft reperfusion. Atrial fibrillation is usually poorly tolerated and requires cardioversion. Nonsustained ventricular tachycardia is frequent, and sustained ventricular tachycardia is usually due to acute electrolyte abnormalities or systemic air embolism from the allograft, after releasing the atrial clamp. Hyperkalemia may ensue after prolonged surgery with hypercapnia, acidosis, and low urine output and should be treated with glucose, insulin, and calcium. Magnesium supplementation may be necessary, and hypomagnesemia may be worsened by calcineurin inhibitors (4).

After the implantation and reperfusion is completed, hemostasis is confirmed. The implantation of the left lung follows the same principles.

At the end of the operation, two 28F chest tubes are inserted on each pleural cavity, one apical (straight chest tube) and one basal (curved chest tube).

Step 7: Clamshell Incision Closure

Four pericostal sutures (VICRYL #2, figure of eight) are placed on each hemithorax. After that, three #5 wires are placed in the sternum.

The pericostal sutures are tied first so that the sternal wires can be secured without undue tension. The muscle, subcutaneous tissue, and skin are sutured in layers with absorbable suture. The anesthetist switches the double lumen to a single lumen tube, and a bronchoscopy is performed for toilet and to recheck the bronchial anastomoses.

LUNG VOLUME REDUCTION SURGERY

LVRS can be performed either unilaterally or bilaterally. Clinical conditions for which unilateral LVRS may be appropriate are summarized in Table 1.

Unilateral LVRS is best accomplished with the patient in the lateral decubitus position, allowing for either a standard

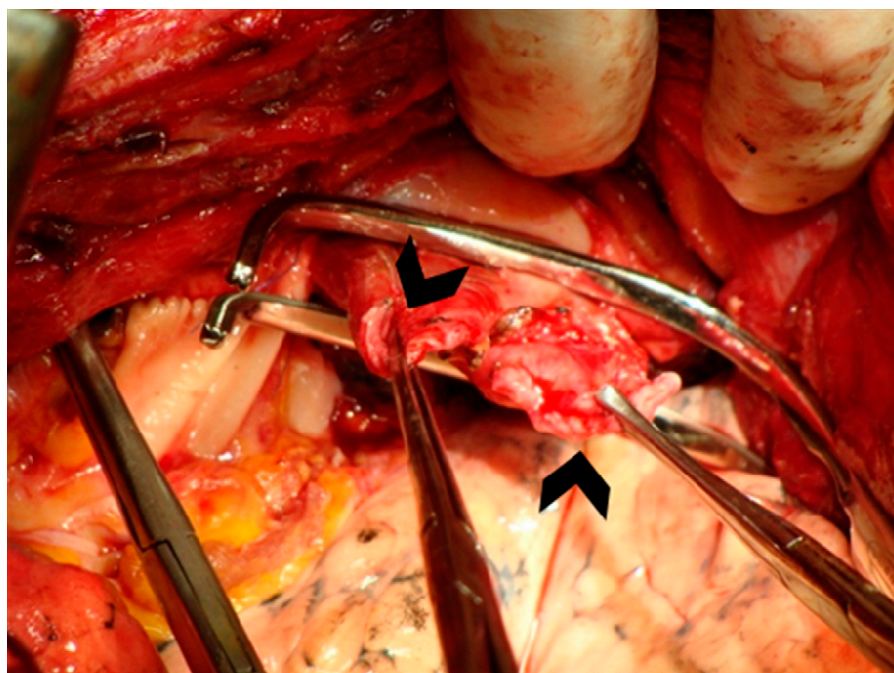


Figure 20. Judd-Allis clamps are applied to the superior and inferior pulmonary vein stumps (*black arrowheads*). An atrial clamp is applied to the recipient left atrium so that a lengthy atrial cuff can be obtained.

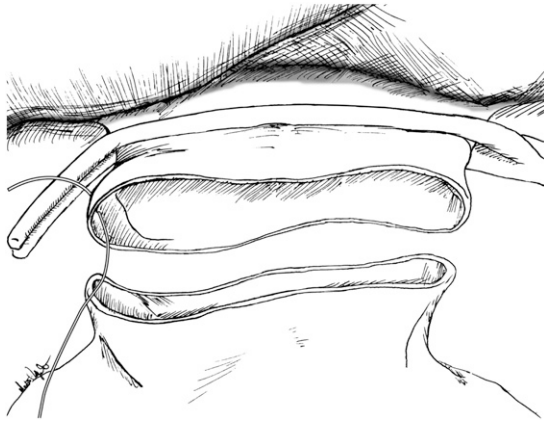


Figure 21. The recipient atrium is to the *top* and the donor atrium is to the *bottom*. The head is to the *left* and the feet to the *right*. On the right side, the top corner stitch is placed first.

posterolateral or muscle-sparing thoracotomy or video-assisted thoracic surgery (VATS) approach.

Bilateral LVRS can be achieved through a median sternotomy, staged anterolateral thoracotomies, or VATS LVRS.

When performing bilateral surgery, consensus opinion is to operate on the worst side first (6). VATS LVRS is our choice.

ANESTHETIC MANAGEMENT

Most authors avoid sedative premedication to avoid respiratory depression in this group of severely ill patients. Others use light sedation with midazolam during invasive pre-anesthetic procedures (6).

Standard monitoring includes invasive arterial monitoring before induction, central venous pressure, pulse oximetry, capnography, core temperature, and ECG. The use of Swan-Ganz catheter and transesophageal echocardiogram (TEE) is more controversial (6).

A thoracic epidural catheter is placed before surgery for optimal postoperative analgesia, if there are no contraindications. Hypotension may ensue when local anesthetics are administered through the epidural catheters due to sympathetic blockade (7). Invasive arterial blood pressure monitoring, vasoactive agents, and fluid administration are necessary (7). It is important to avoid fluid overload to allow early extubation (7). We use both epidural analgesia and preemptive local anesthesia. Nonsteroidal agents are also used postoperatively to supplement analgesia (7).

Before induction of anesthesia, the patient is preoxygenated in a partial sitting position. Intravenous induction with all commonly used agents has been reported. Pancuronium is not a good option once early extubation is planned. The use of both volatile agents or propofol has been described for anesthesia maintenance. Use of short-acting intravenous agents is the key consideration. Propofol preserves the hypoxic pulmonary vaso-

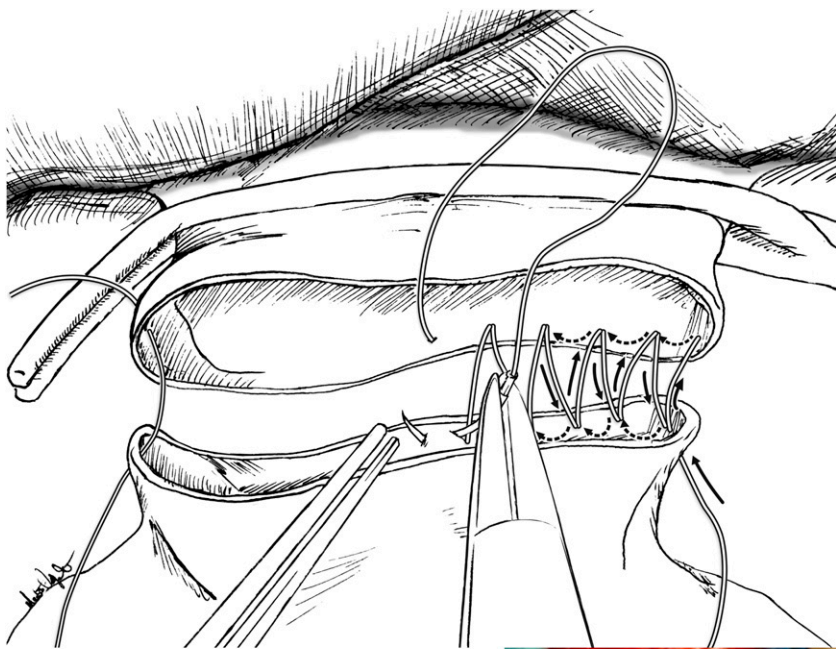
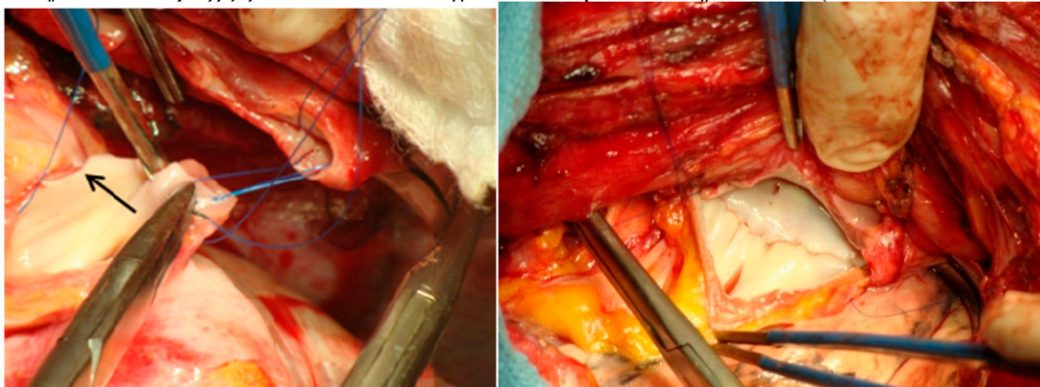


Figure 22. The back wall of the atrial anastomosis. It is very important to place the suture close to the previous one as shown in the picture to achieve a hemostatic suture line. The photograph shows the evertting mattress suture being placed in the donor atrial cuff running from the bottom to the top as it is done on the right side. The needle goes through the full thickness of the atrial wall, approximately 2 to 3 mm from the edge. The final result is perfect endothelium to the endothelium apposition. In this way, no muscle remains inside the atrium, decreasing the potential for thrombosis or cerebrovascular accidents. On the *left side*, we first place the bottom corner suture and begin suturing from the top down, using the same evertting mattress suture.



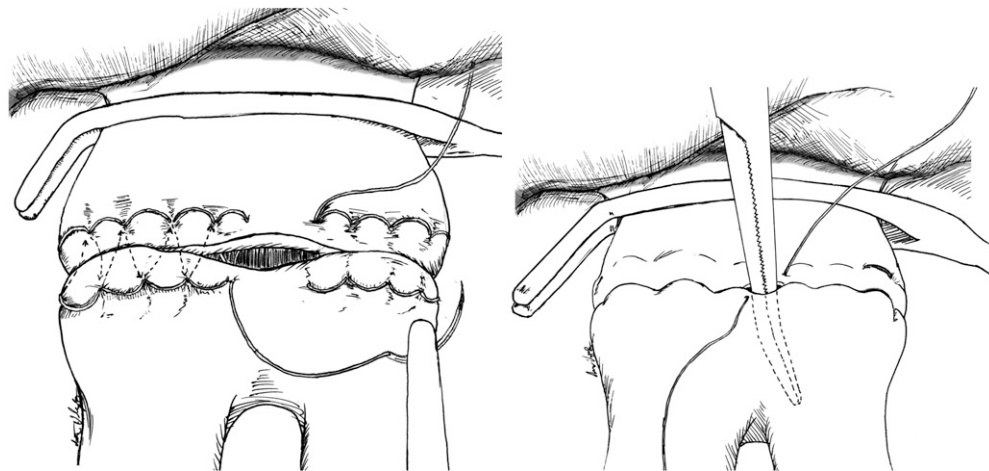


Figure 23. The anterior atrial wall is anastomosed using the same evert mattress suture technique as shown in the figure. We start it from the top corner to the middle of the anterior wall and then from the bottom corner to the middle. The sutures are not tied. When the atrial anastomoses is finished, the anaesthetist is asked to gently inflate the implanted allograft. The newly implanted lung is ventilated with an $F_{I_{O_2}}$ of less than 50% and the contralateral native lung with an $F_{I_{O_2}}$ of 100%. A curved clamp is inserted in between the untied sutures into the inferior pulmonary vein to keep the atrial suture line open for de-airing. The pulmonary artery

clamp is gradually released over a period of 10 minutes to provide controlled pressure reperfusion. The lung is de-aired as follows: (1) blood is allowed flow out the untied atrial suture line, (2) the mosquito clamp is removed, (2) the left atrial clamp is released, and (4) then the left atrial suture is tied.

constriction, thus avoiding an increase in oxygen shunt fraction (7). Nitrous oxide has been avoided. Due to the severity of the bullous disease and associated dead space, uptake and distribution of inhalational agents is unpredictable, and delayed awakening may occur (7).

Emphysema, with its severe airflow obstruction coupled with the need of positive-pressure ventilation during general anesthesia and one-lung ventilation, can lead to severe gas trapping or dynamic hyperinflation and pneumothorax, with hemodynamic instability. Disconnecting the ventilator circuit from the endotracheal tube leads to rapid resolution of systemic hypotension in that situation. Ventilating the patient with small tidal volumes and allowing longer expiratory times can avoid dynamic hyperinflation (auto-PEEP, air trapping) and its deleterious effect on venous return and systemic hypotension. Both pressure-controlled or volume-controlled ventilation have been successfully used. A ventilator capable of measuring auto-PEEP is helpful. Pressure-controlled ventilation limits airway peak pressure and may decrease the chance of barotrauma. Volume-controlled ventilation can minimize auto-PEEP when using low tidal volumes (5 ml/kg during one-lung ventilation). Inspiratory time:expiratory time ratios of 1:3 to 1:5 and low respiratory rates are used (7). Hypercarbia is a consequence of low tidal volume ventilation, and maneuvers to increase minute ventilation must be used when pH falls below 7.2: (1) increase of ventilatory rate, (2) aspiration of secretions, (3) adequate muscle relaxation, and (4) aggressive treatment of bronchospasm. When hypoxia occurs during one-lung ventilation, one can: (1) increase $F_{I_{O_2}}$, (2) apply PEEP in the dependent lung, and (3) temporarily occlude PA flow to the nonventilated lung (7).

TABLE 1. INDICATIONS FOR UNILATERAL LUNG VOLUME REDUCTION SURGERY

Unilateral or severely asymmetric emphysema
Contralateral pleurodesis
Contralateral thoracotomy with or without prior lung resection
Ipsilateral lung cancer resection with contralateral LVRS for a patient with limited lung function
Hemodynamic instability during the first side of planned bilateral LVRS
Massive air leak during the first side of planned bilateral LVRS
Severe native lung hyperinflation after single lung transplantation for emphysema

Definition of abbreviation: LVRS = lung volume reduction surgery.

Patients with emphysema may also have occult coronary disease, which can manifest abruptly in the operating room. Careful assessment of cardiac disease before selection for LVRS is necessary. LVRS carries a risk of significant cardiac stress, and intraoperative myocardial infarction has been reported. A pharmacologic stress test is recommended to screen for occult cardiac ischemia, and a coronary angiogram may be necessary. The use of β -blockers and nitrates during the perioperative period should be considered. The occurrence of bronchospasm should be monitored (7).

Air leak is an important potential complication of LVRS, due to disruption of the suture line or adjoining lung tissue. Because of that, low tidal volume ventilation, longer expiratory times to avoid hyperinflation during LVRS, and early extubation in the operating room are desired. To accomplish early extubation, the anesthesiologist must use short-acting anesthetic agents, provide excellent postoperative pain control, and maintain the patient in a euolemic and normothermic state (7).

Surgery is performed under general anesthesia with left-sided double-lumen endotracheal tube to allow single-lung ventilation (2). A bronchial blocker may also be used. Regardless of the method for one-lung ventilation, the tube position must be assured by bronchoscopy. Low tidal volume during exposure and apneic oxygenation during stapling the diseased lung may be used when one-lung ventilation is problematic. Due to severe obstructive lung disease and decreased elastic recoil, deflation of the operative lung takes longer. The lung may not deflate even during one-lung ventilation. Suctioning of secretions and gentle pressure exerted on the operative lung by the surgeon may help with deflation of the lung (7).

VIDEO-ASSISTED LUNG VOLUME REDUCTION SURGERY

VATS LVRS can be performed sequentially on two lungs under the same anesthetic procedure.

SURGICAL TECHNIQUE

We use supine positioning for upper lobe disease (Figures 24a and 24b). For lower lobe and if we anticipate adhesions, lateral positioning is used but troublesome. A 30-degree video-telescope enhances visualization in either patient position. The technique used at the Toronto General Hospital is depicted in Figures 25 and 26.

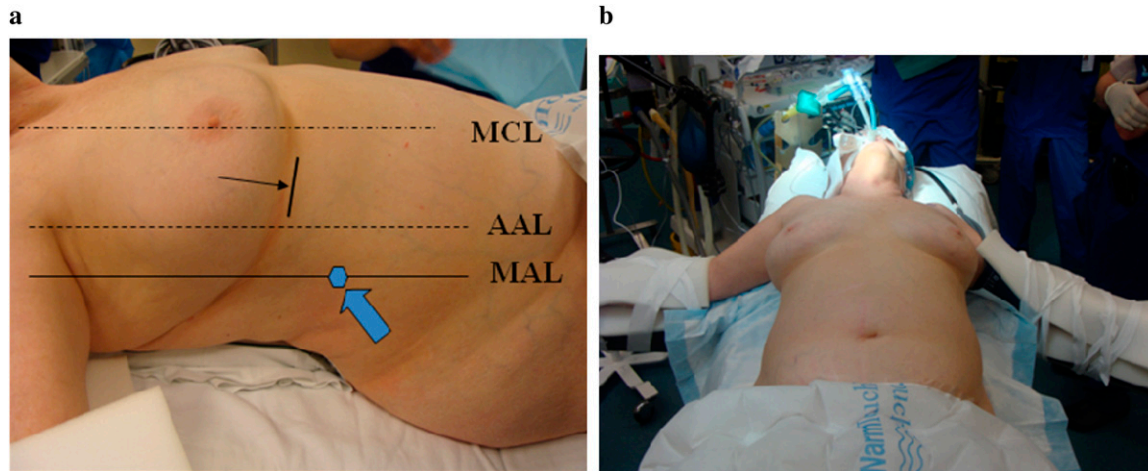


Figure 24. (a) Port positioning- The ports typically involve a midaxillary 9th intercostal space camera port (blue arrow) and a 6th intercostal space port between anterior axillary line (AAL) and mid-clavicular line (MCL) as indicated by the black arrow. Port placement is quite liberally adjusted depending on the size and shape of the hemithorax, as hyperinflation can cause distortion. (b) We use supine positioning for upper lobe disease. For lower lobe and if we anticipate adhesions, lateral positioning is used, but it is troublesome. A roll is placed under the shoulders.

Care must also be taken to ensure that the chest drains after LVRS in the first pleural space remain unobstructed during contralateral LVRS to avoid tension pneumothorax and intraoperative cardiovascular and/or respiratory collapse (3). Finally, two chest tubes are inserted into the chest cavity at the end of the procedure. The emphysematous pathologic specimens are shown in Figures 27A and 27B.

The operated lung is not aggressively recruited; rather the clamp is simply removed from that limb of the double lumen tube and the lobe is re-inflated gradually.

No clear differences in outcome between median sternotomy and bilateral video-assisted thoracoscopic surgery have been shown (2). NETT surgeons found that the two approaches resulted in similar early and late mortality, similar types and rates of complications, and produced similar improvements in spirometry, exercise capacity, and quality of life extending to 24 months of follow-up (5). The operative results alone are impressive, with a 90-day mortality in NETT between 4.6% (VATS) and 5.9% (sternotomy) versus the pre-NETT Medicare 90-day mortality rate of 14.4% (8).

Regardless of the approach, LVRS is achieved by resecting 20 to 30% of each lung or as high as 60% of hemithorax volume.

The staple lines are often buttressed with bovine pericardial or polytetrafluoroethylene strips to reduce air leaks.

POSTOPERATIVE MANAGEMENT AND OUTCOMES

LVRS carries a high morbidity, with complication rates up to 85 to 100% in some series, and up to 60% excluding air leaks (2). Aggressive management of early postoperative complications, including air leaks, respiratory failure, arrhythmias, and hemorrhage, can also be expected to improve outcomes (9).

Early extubation is beneficial to avoid coughing or gagging and to minimize the duration of positive-pressure ventilation of the fragile, operated lungs. The Pa_{O_2} is maintained close to baseline because a high Pa_{O_2} may be deleterious in a patient with preoperative CO_2 retention (11). Szekely and coworkers (cited by Brister and coworkers, Reference 7) found that a resting Pa_{CO_2} greater than 45 mm Hg together with a six-minute-walk distance less than 200 m are risk factors for poor outcome, defined as death within 6 months or a hospital course of greater than 3 weeks. O'Brien and colleagues (cited by Brister and coworkers, Reference 7) found no increased mortality in 15 patients with hypercapnic emphysema (Pa_{CO_2} 55-67 mm Hg) compared with a population with eucapnea.

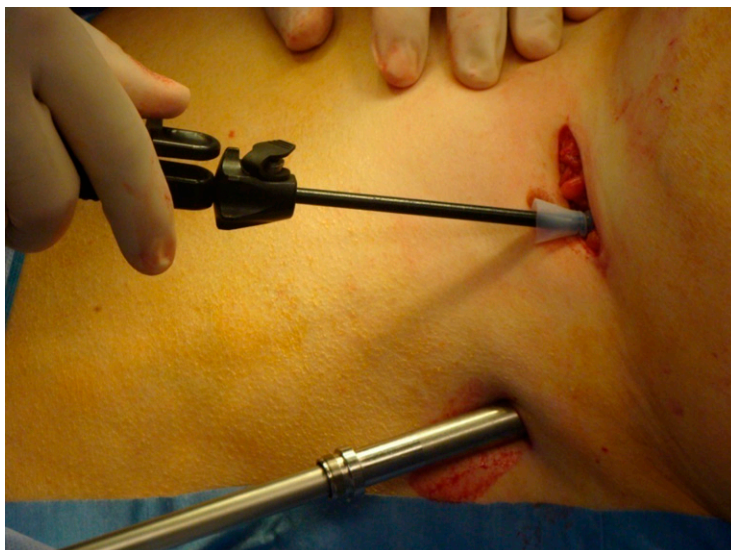

Figure 25. The anterior port site is made deliberately large enough to allow a small grasper and a stapler. We often use a 5-mm port to pass through a separate passageway in the intercostal muscle and pass the stapler without a port.

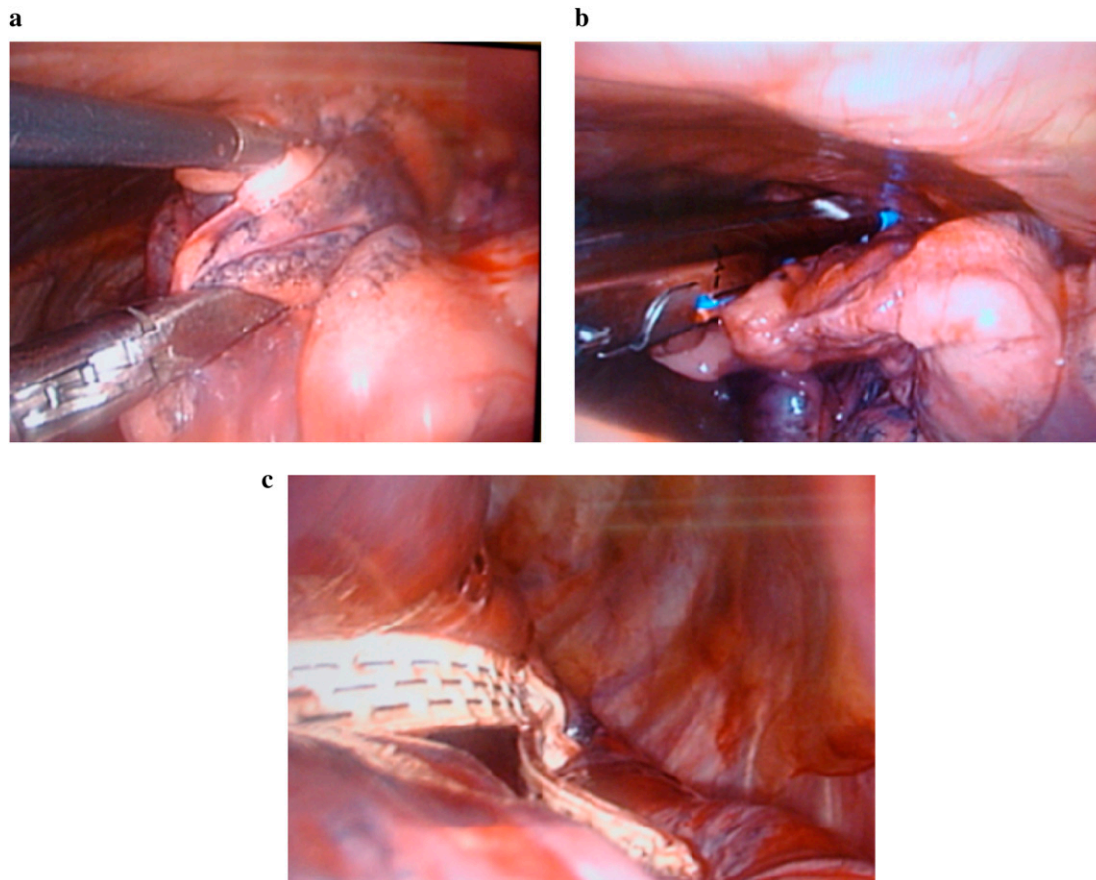


Figure 26. (a) Next, the endostaplers are loaded with a peri-strip to reinforce the staple line. Before application of the stapler, we use an Endo-Duval grasper, which has a very wide opening capability to compress the lung along the line of proposed division. Panel b shows the endostapler applied. After compressing the lung, the stapler is carefully advanced to prevent tearing of the lung, which can be extremely fragile, and applied. This process is repeated several times to complete the planned volume reduction (7–10 fires for each lobe). Panel c shows the staple line with the pericardium reinforcement. It is important to move smoothly and expeditiously to avoid hematomas within the lung.

Keenan and coworkers found increased mortality when Pa_{CO₂} was greater than 50 mm Hg (10).

Thoracic epidural analgesia is maintained for 4 to 5 days after surgery. Oral opioids are avoided until the epidural

catheter is removed. Early mobilization and aggressive chest physiotherapy are also critically important (11).

Nebulized bronchodilators should be administered for at least 48 hours before resuming usual bronchodilator therapy.

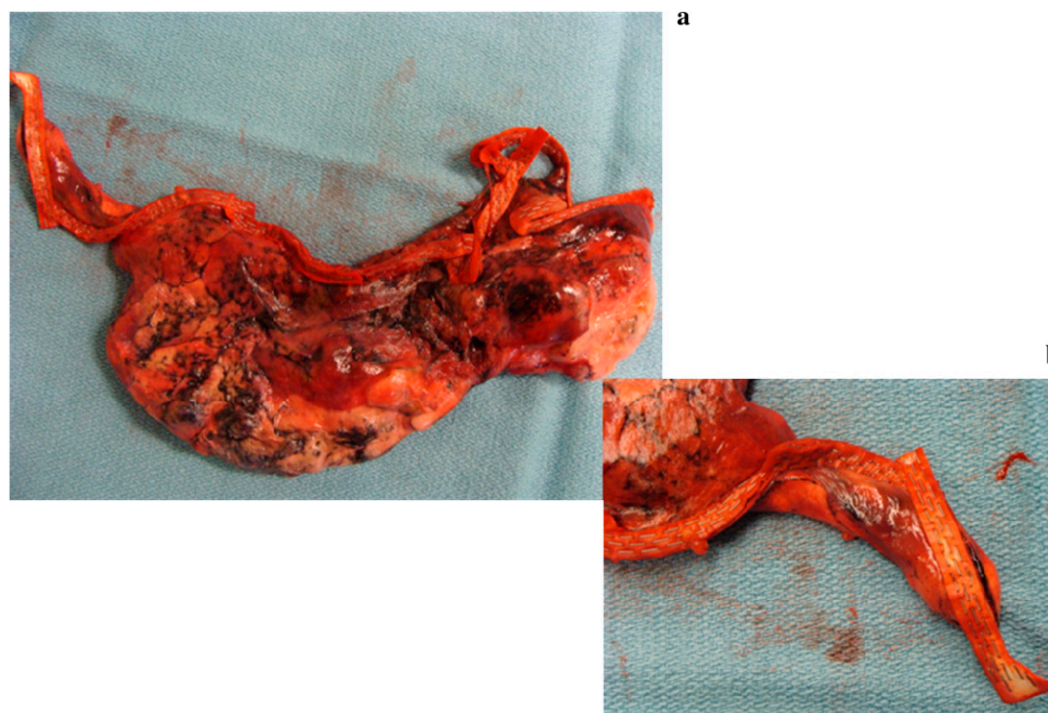


Figure 27. The specimens resected from the right upper lobe (a) and from the left upper lobe (b).

TABLE 2. COMMON POSTOPERATIVE COMPLICATIONS

Respiratory
Prolonged air leak (persistent after 7 d; up to 60%)
Large pleural space
Respiratory failure and prolonged mechanical ventilation (reintubation 12%; mortality 40%)
Pneumonia (up to 20%; carries a 40% mortality)
Cardiovascular
Arrhythmias (23.5%)
Myocardial ischemia and cardiac arrest (1%)
Gastrointestinal (7%)
Bleeding
Ileus
Bowel perforation
Other
Deep sternal wound infection (rare)
Deep venous thrombosis and pulmonary embolism (incidence unknown)

Retained secretions may require nasotracheal suctioning; fiberoptic bronchoscopy may be needed up to twice daily for retained secretions, and a 5.4 F minitracheostomy tube can be inserted through the cricothyroid membrane if more frequent suctioning is necessary (2).

Table 2 shows the common postoperative complications encountered in LVRS (2, 7).

Patients undergoing LVRS can anticipate a postoperative mortality of 5.5%, major pulmonary morbidity of 30%, and cardiac morbidity of 20% (12).

Patients spend significant time recovering after LVRS, with nearly 30% of patients still hospitalized or in rehabilitation facilities 1 month postoperatively and 15% still not at home 2 months after the operation (13).

Conflict of Interest Statement: None of the authors has a financial relationship with a commercial entity that has an interest in the subject of this manuscript.

Acknowledgment: The authors are grateful to Matthew Villagonzalo for his excellent drawings done for this manuscript.

References

- Mannino DM, Watt G, Hole D, Gilis C, Hart C, McConnachie A, Davey Smith G, Upton M, Hawthorne V, Sinn DD, et al. The natural history of chronic obstructive pulmonary disease. *Eur Respir J* 2006;27:627-643.
- Sayeed RA, Waddell TK. Lung volume reduction surgery. In: Klein A, Vuylsteke A, Nashef SAM, editors. Core topics in cardiothoracic critical care. Cambridge: University Press; 2008. pp. 390-394.
- DeCamp MM Jr, McKenna RJ Jr, Deschamps CC, Krasna MJ. Lung volume reduction surgery: technique, operative mortality, and morbidity. *Proc Am Thorac Soc* 2008;5:442-446.
- McRae K. Anesthesia for intrathoracic transplantation. In: Cheng DCH, David TE, editors. Perioperative care in cardiac anesthesia and surgery. Philadelphia: Lippincott, Williams, & Wilkins; 2006. pp. 49-63.
- Meyers BF, Sundharsan RS, Guthrie T, Cooper JD, Patterson GA. Bilateral sequential lung transplantation without sternal division eliminates posttransplantation sternal complications. *J Thorac Cardiovasc Surg* 1999;117:358-364.
- Hillier J, Gillbe C. Anaesthesia for lung volume reduction surgery. *Anaesthesia* 2003;58:1210-1219.
- Brister NW, Barnette RE, Keresztury KV. Anesthetic considerations in candidates for lung volume reduction surgery. *Proc Am Thorac Soc* 2008;5:432-437.
- National Emphysema Treatment Trial Research Group. Safety and efficacy of median sternotomy versus video-assisted thoracic surgery for lung volume reduction surgery. *J Thorac Cardiovasc Surg* 2004;127:1350-1360.
- Health Care Financing administration. Report to Congress: lung volume reduction surgery and Medicare coverage policy. Implications of recently published evidence. Washington DC: Department of Health and Human Services; 1998.
- Keenan RJ, Landreneau RJ, Sciarba FC, Ferson PF, Holbert JM, Brown ML, Fetterman LS, Bowers CM. Unilateral thoracoscopic surgical approach for diffuse emphysema. *J Thorac Cardiovasc Surg* 1996;11:308-316.
- Sharafkhaneh A, Falk JA, Minai OA, Lipson DA. Overview of the perioperative management of lung volume reduction surgery patients. *Proc Am Thorac Soc* 2008;5:438-441.
- Naunheim KS, Wood DE, Krasna MJ, DeCamp MM Jr, Ginsburg ME, McKenna RJ Jr, Criner GJ, Hoffman EA, Sternberg AL, Deschamps C. Predictors of operative morbidity and mortality in the national emphysema treatment trial. *J Thorac Cardiovasc Surg* 2006;131:43-53.
- National Emphysema Treatment Trial Research Group. A randomized trial comparing lung-volume-reduction with medical therapy for severe emphysema. *N Engl J Med* 2003;348:2059-2073.